
RARE CARDIAC ANOMALIES.

CONGENITAL AORTICO-PULMONARY COMMUNICATION;
COMMUNICATION BETWEEN THE AORTA AND THE
LEFT VENTRICLE UNDER A SEMILUNAR VALVE.

BY LUDVIG HEKTOEN.

In the following will be described two decidedly uncommon defects—one of the septum between the pulmonary artery and the aorta, and the other of the base of the right anterior aortic valve, the latter being, as far as I can tell, absolutely unique. The patients, two newborn infants, died in the Presbyterian Hospital while under the care of Professor Cotton, and the postmortems were made in my laboratory. Both cases have been previously recorded by Professor Cotton,¹ but with especial reference to certain clinical manifestations, particularly anuria, hence the reason for this additional report.

1. *Large defect in the septum between the pulmonary artery and the aorta, the heart normally developed; general infection with B. mucosus capsulatus. Postmortem (675).*—Well-developed, fairly well-nourished male infant, 51 cm. long, weighing 2657 grams. There are no external malformations. The surface of the body, both anteriorly and posteriorly, is bluish-red in color. The umbilical cord is dry and separating at the navel. The abdomen is somewhat distended.

The abdominal cavity is empty, the lining smooth. The diaphragm reaches to the fifth right and sixth left ribs.

The pleural cavities are empty and smooth as to lin-

ing, the visceral pleura being the seat of many hemorrhagic extravasations.

The pericardium is also smooth, the cavity contains a small amount of clear fluid.

The mouth, pharynx, larynx, trachea, and esophagus are normal. The thyroid is of usual size; the thymus rather small.

The lungs are fully distended and show many small, deeply-congested spots throughout the parenchyma; no bronchitis.

The heart presents a much larger right than left ventricle; the latter is situated more behind the right than usual. The walls of the two ventricles are of about the same thickness, but the cavity of the right ventricle is much the larger. The tricuspid and mitral valves are quite normal; the pulmonary and aortic valves are also well formed and normal. There is an oval defect, about 1.5 cm. in its greatest diameter, between the pulmonary artery and the aorta, so that a little above their beginning the aorta and the pulmonary artery have a common trunk from which emerge in the usual places, relatively, the right and left pulmonary arteries and the branches of the arch of the aorta (Fig. 1). The greatest diameter of this common trunk is 3 cm. Between the semilunar valves arises a septum with a somewhat rounded, concave upper margin; from the base of the pulmonary semilunars the septum rises to a height of 3 mm., while from the base of the aortic semilunars the septum is 1 cm. high. The ductus arteriosus is fully patent and quite large, and the part of the aorta distal to the duct is wider than the transverse part proximal to the duct. The foramen ovale is widely open. The veins—pulmonary and caval—are quite normal. The ventricular septum is normal.

The stomach and intestines are normal.

The pancreas is normal.

The liver and spleen are congested, the liver being

soft and mottled, yellow and red. The spleen weighs 10 grams, the liver 110 grams. The adrenals are normal, weighing 11 grams.

The urogenital organs are normally formed and situated. The bladder contains a small amount of turbid urine, the mucous membrane immediately about the

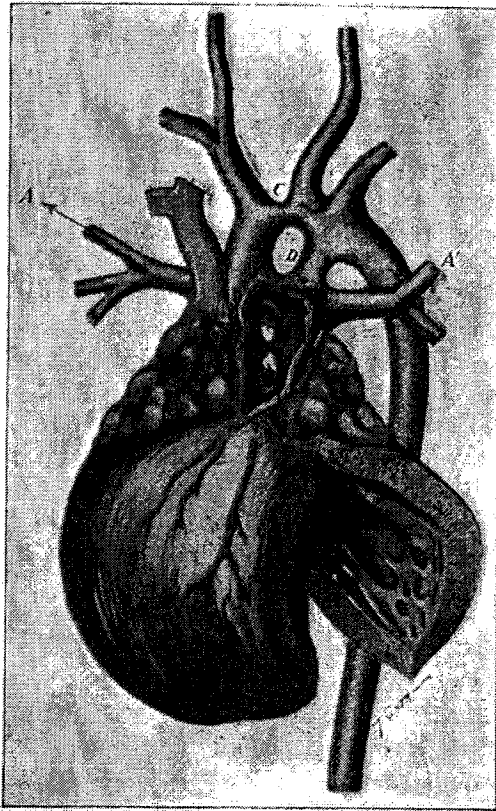


Fig. 1.—Aortico-pulmonary communication. *A*, right pulmonary artery. *A'*, left pulmonary artery. *B*, opening of aorta from left ventricle into common trunk. *C*, partial obliterated aortic arch. *D*, large patent ductus arteriosus. *E*, hypertrophied right ventricle.

ureteral orifices is swollen and red. There is no dilatation of the ureters and pelvis. There is marked uric

acid infarction in both kidneys with some congestion of the pyramids. The kidneys weighed 26 grams.

The brain and its membranes are normal; weight, 1381 grams. The lines of ossification are even and regular; Bichat's center measures 4 mm.

Bacteriological Examination.—Smears and cultures from the heart's blood, the lungs, the liver, the spleen, and the kidneys all show a bacillus with the morphological, cultural, and pathogenic characteristics of *bacillus mucosus capsulatus*.

Histological Examination.—The heart shows normal structural conditions.

The lungs are the seat of an extensive hemorrhagic infarction, the alveoli and bronchioles in places being filled to distention; otherwise no changes.

The liver is the seat of a marked passive congestion with fatty infiltration of the liver cells and some recent increase in the periportal connective tissue, which is rather cellular.

The cortex of the kidney shows cloudy swelling of the epithelium of the convoluted tubules. In the medulla the uriniferous tubules are crowded full with a granular material which stains light blue with hematoxylin; the epithelial lining is intact and the vessels uniformly distended with blood.

Sections stained with methylene-blue show occasional encapsulated short bacilli here and there in all the organs, especially among extravasated corpuscles and in the capillaries of the lungs.

Instances of direct communication between the aorta and the pulmonary artery, caused by congenital defect in the septum of the arterial trunk, are described by Elliotson,² Wilks,³ Fräntzel,⁴ Baginsky,⁵ Cæsar,⁶ Girard,⁷ and Richards;⁸ Rauchfuss⁹ and Gerhardt¹⁰ also each mention an instance. These seem to be all the instances recorded in literature. The defect is rare. Virchow, in discussing Baginsky's case, remarked that he

had not seen an example before. As far as I have been able to learn, there is no previous instance recorded in American literature.

In all these instances (except Richards' case) there is a simple communication between the aorta and the pulmonary artery, the opening being situated a short distance above the semilunar valves, round or triangular in outline, and 10 to 12 mm. in diameter. Other malformations are not noted, and evidences of endocarditis or angeitis are wanting altogether. This form of communication is consequently of congenital nature, and it is to be distinguished from the more frequent, similarly located communications of acquired, accidental origin.¹¹ It is also to be held distinct from communication between the pulmonary artery and the arch of the aorta through a persistent ductus arteriosus, which, when uncommonly short, may lead to a close approximation of the two vessels. The location of this communication would be different, namely, at the arch of the aorta.

Closely related to direct congenital communication between the pulmonary artery and the aorta is congenital communication between the beginning of the aorta and the right ventricle. Such cases are described by Cayla,¹² Charteris,¹³ and Livingston.¹⁴ In Cayla's case (man, aged 34) a canal passed from the upper part of the ventricle into the aorta just above the valves, which was somewhat irregular. Quenu suggests that the defect was caused by failure of union between the septum of the bulb and the interventricular septum. Charteris describes an opening "immediately under" the right valvular aortic curtain communicating with the right ventricle. This occurred in a man, aged 53 years, and perhaps a question might be raised as to its congenital nature.

Livingston's case occurred in a child four months old. Just at the beginning of the aorta a communication led into the right ventricle. There were only two aortic

TABLE OF CASES.

Author.	Age.	Sex.	Clinical symptoms.	Description of the defect.	Ductus arteriosus.	Remarks.
1. Ellipton. 2. Wilks.	Young. 8 mo.	F.	Strong systolic bruit at base; no cyanosis; ascites.	Opening admitted end of finger. Opening admitted goose-quill.	Closed. Closed.	No other anomalies. Pulmonary artery large, aorta small; no traces of influenza.
3. Frantzel.	27 yrs.	F.	Dyspnea and palpitation as long as she had memory. Increased cardiac dullness; dropsy; cyanosis; changing auscultatory phenomena; at first systolic and diastolic murmur; later diastolic murmur was replaced by double tone; diastolic murmur same distribution as in aortic insufficiency.	1 cm. above margin of aortic valves a round opening 12 mm. in diameter.	Closed.	Dilatation and hypertrophy of heart; right pulmonary artery enlarged from aortic just below arch; esophagus normal; no endocarditis; thrombi in left ventricle; impunctate, enlarged aortic, vertebral and left subclavian given off by arch; tubercles. (Postmortem by Pathologist.)
4. Bucinsky.	4 yrs.	F.	Under observation since 8 days after birth; there was cough, dyspnea, hoarseness, cardiac irregularity, systolic and diastolic murmurs and repeated disturbances of compensation; scarlet fever and nephritis.	Opening between aorta and pulmonary artery 1 cm. in longest diameter; margins somewhat thickened; almost triangular in outline; base on level with upper border of left pulmonary semilunar valve and 1 cm. above free margin of aortic valves. Rounded opening with sharp margins.	Closed.	Parental syphilis; nephritis; hypertrophy of both ventricles; more of the right; the left being the one most dilated.
5. Gerhardt.	3 mo.	F.	No details except rough sound over heart.	Free margin of aortic valves.	Closed.	No endocarditis; specimen in Museum of Guy's Hospital.
6. Rauchfuss.	Nurse.	F.	No details.	Free margin of aortic valves.	Closed.	No endocarditis; specimen in Museum of Guy's Hospital.
7. Casar.	9 yrs.	M.	Yawsels since three months. Passed through measles, bronchitis, pneumonia; ostia 1-3 year; right hemiplegia since 3; died at 9 in convulsions; no murmur.	Communication between aorta and pulmonary artery size of a sixpenny.	Not stated.	Marked fenestration of aortic valves; ascending aorta as large as an adult; pulmonary and venous tubes with large chronic thrombi with calcareous mass in l. hemisphere.
8. Girard.	37 yrs.	M.	Small box at 1; dyspnea and cardiac distress since then; otitis; severe fever at 20 with swelling of legs; also other illnesses. Four years before death; dyspnea and hematuria; systolic murmur with accentuation of mitral insufficiency; renal embolism, hematuria. Shortly before death, dyspnea, cyanosis, gallop rhythm, enlargement of heart.	11 mm. above free edge of aortic valve opening into pulmonary artery 10 mm. in diameter; no change in intima of aorta and pulmonary arteries.	Not stated.	Heart weighed 570 grams hypertrophied especially marked of right side, from bus in arch of right ventricle; endocardium normal; coronary arteries large; extensive congenital atherosclerosis.
9. Richards.	30 yrs.	M.	Breast under until 3 months before death. Two loud, systolic and diastolic murmurs; hypertrophy of heart; dyspnea; anaesared.	Behind larger of bicuspid aortic valves circular opening into pulmonary artery admitting little finger; margins membranous, smooth; passage somewhat funnel-shaped.	Not stated.	Hypertrophy and dilatation of heart; no endocarditis; pulmonary artery dilated above opening from aorta; defective interventricular septum.
10. Cotton. Hektoen.	3 days.	M.	"Blue baby." Anuria.	Oval defect 1.5 cm. in its greatest diameter in septum above semi-lunar valves.	Patent, rather large.	Foramen ovale open; no other defects; right ventricle hypertrophied.

valves. White¹⁵ and Tate¹⁶ also describe somewhat similar defects. Lediberder's¹⁷ case was more complicated. Here there was pulmonary stenosis, closed foramen ovale, open ductus arteriosus, and communication between pulmonary artery and aorta. I have not looked up the details.

In White's case (boy, aged 15 years) the whole upper septum was deficient in thickness, and there was failure of complete closure at the right of the "undefended space." A small aneurysm had formed behind the right aortic valve and ruptured into the right ventricle.

Tate describes a trumpet-shaped membranous tube extending from a rounded opening at the lower part of the anterior aortic valve into the right ventricle. At the same time there was a saccular projection in the right ventricle at the "undefended space."

Congenital communication between the pulmonary artery and the aorta are to be traced back to developmental anomalies of the septum that divides the primary arterial bulb into two large vessels. A defect of this sort dates from some period of intra-uterine life before the seventh or eighth week, because at this time the pulmonary artery and the aorta are completely separated (Born,¹⁸ His¹⁹). Based upon the presence of fenestrations of the aortic valves in the case of aortic and pulmonary opening described by Cæsar. H. Vierordt²⁰ suggests that the septal defect may be the result of an extension to the arterial wall of the process of hollowing out, whereby the primary endothelial cushions are converted into thin leaflets. At all events, the uncomplicated nature of the defect in most of the cases, including the one now reported, indicates that the defect is the result of abnormal developmental processes rather than of inflammatory changes (endangeitis). Similarly, communication between the aorta and the right ventricle may be ascribed to faulty development of the aortic septum; complete union between the interventricular sep-

tum and the aortic septum may fail to take place during the time that the conus arteriosus takes up part of the auriculo-ventricular orifice (about the seventh week—Born).

The clinical features of direct congenital communication between the pulmonary artery and the aorta are considered by L. Brocq,²¹ H. Vicroridt,²² and Leon Cazin.²³ The latter author made the clinical diagnosis of this lesion in a young woman, but in the absence of post-mortem examination its correctness will always be open to doubt. L. Brocq²⁴ shows that the location and the mechanical consequences of congenital aortico-pulmonary communications are the same as in accidental communications; but in the first the lesions are more pure, hence the true symptomatology should be sought in the congenital form; but the number of instances of the latter is as yet rather small for drawing a definite clinical picture. In most of the recorded cases the lesion was a surprised revealed by the autopsy.

The cases are equally distributed between the sexes. The age attained varies from a few hours to thirty-seven years.

In all the cases that died at an age of from four to thirty-seven years definite symptoms of heart disease were present; in three of them the heart lesion seems to have been the cause of death (Fräntzel, Baginsky, Richards); in two the cardiac disease was complicated by meningeal and urogenital tuberculosis (Cæsar, Girard). In the case now reported there was a general and marked infection with *B. mucosus capsulatus*.

By reference to the table of cases it is seen that the statements with respect to cardiac murmurs vary much. The most common murmur is a double one—systolic and diastolic—at the base; in Girard's case there was also persistence and accentuation of the second sound. In several cases the changing, uncertain character of the murmur is noted.

Occasionally hypertrophy of the heart, especially at the right ventricle, quite commonly noted at the autopsies, was demonstrated by the physical examination. In all cases where the condition of the ventricle was noted there was found more or less hypertrophy, sometimes only of the right ventricle, but occasionally of both, the right being the larger; the reason for this being that the right ventricle contracts against the current sent out by the left side of the heart, which is the naturally stronger side.

Dyspnea, cyanosis, ascites, and anasarca were present in Fräntzel's case, and in Baginsky's, Girard's, Richards', and Wilks' cases some one of these evidences of grave disturbance of the compensation are noted, cyanosis being definitely mentioned by Cæsar and Girard, as well as Fräntzel; but the statements in regard to cyanosis are hardly definite enough to determine whether it was due to the defect itself or to the resulting cardiac insufficiency. In the infant that I examined cyanosis was fairly well marked. In this case there was also complete anuria.²⁵

2. *Regurgitation through smooth depression under base of anterior aortic valve, which is attached to and carried across by a tendinous bridge: hypertrophy of the heart; dilated arterial duct; congestion. Postmortem (838).—*A well-developed, well-nourished female, newborn child; the body still warm; the umbilical cord is dry and there is a line of separation around its insertion at the navel; rigor is strong; the surface of the body is livid.

The serous cavities of the trunk are empty; their linings smooth. The diaphragm reaches to the fifth ribs.

The pharynx, larynx, and trachea are normal. The thymus and thyroid are normal. The lungs are distended and contain many areas of hemorrhage, subpleural and deep-seated. The lungs crepitate freely; no bronchitis; much congestion.

There are subepicardial extravasations at the base of the heart. The heart is distended with blood. There is great enlargement of the heart, especially the left ventricle. From base to apex the heart is 4.5 cm. long and 5 cm. across the widest base. The heart weighs 42 grams. The endocardium of the right side is normal. The depth is 4 cm.; the wall is 3 mm. thick. The tricuspid orifice is 1 cm. in diameter. The foramen ovale is patent, and the ductus arteriosus is large and widely open, the aortic orifice of the duct measuring 6 mm. across; it is normally located. The pulmonary artery is normal. The

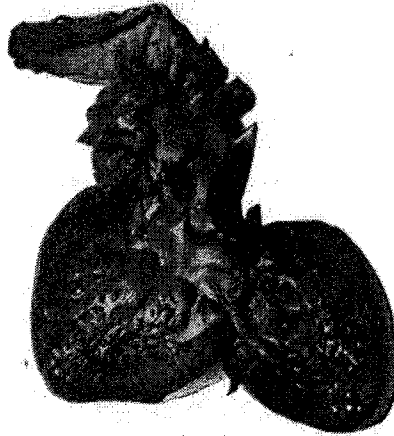


Fig. 2.—Bulging at aortico-septal junction and communication between aorta and left ventricle under anterior aortic leaflet.

mitral orifice is small—about 0.5 cm. in diameter; the auricular surface of the valve is smooth, but somewhat nodular, and there are also slight thickenings upon the chordæ tendineæ; no ulceration; no thrombosis. The aortic valves are large, higher than normal (about 6 mm.), of irregular thickness, but smooth, there being small, delicate, reddish nodules upon them, so that they appear somewhat deformed.²⁰ There are no distinct lunulæ or corpora arantii. There are three valves, but the anterior segment is attached to an irregular, dense,

and firm, band-like bridge, 2 mm. thick, which extends across an oval depression in the upper part of the interventricular septum and the lower aspect of the aorta, which here presents a marked bulging anteriorly between the aorta and pulmonary artery (Figs. 2 and 3). It looks as if the lower end of the aorta and the interventricular septum had failed to develop fully. The junction of the septum and of the aorta occurs under the bridge, the line of exact junction being rather indefinite. The depression is 1.5 cm. vertically, 1 cm. across, and 8 mm. deep. The bulging is smooth, and there is no communication between it and the pulmonary artery or the left ventricle. The left half of the upper limit of the depression is marked by a rather sharp ridge in the aorta, but the right half is marked by a rounded bulging. Viewed from the right ventricle the "undefended space" appears as a triangular area near the center of the depression in the aorta. The interventricular septum is not perforated. The left ventricle is 4 cm. deep, and the wall is 5 mm. in average thickness. The beginning of the aorta, just above the sinuses of Valsalva, is wider than usual, but smooth; it is 2.5 cm. in circumference.

The right coronary arises in the deep sinus behind the anterior semilunar valve, near the right end of the bridge. Its distribution is normal; some of the branches at its beginning are rather large.

The left coronary arises in the sinus of the left posterior semilunar valve; the opening is a little higher than the right. The upper margin of the sinus is outlined by a rather sharp ridge.

The liver is large, congested, bluish in color, and it weighs 127 grams; it is smooth.

The spleen is congested and weighs 7 grams.

The kidneys show marked uric-acid infarction in the medullary pyramids. The ureters and bladder are normal. The adrenals are normal.

The stomach and intestines are normal.

The brain could not be examined.

Bacteriological Examination.—Smears and cultures from the heart's blood and from the large organs do not contain any bacteria.

Histological Examination.—The alveoli in some parts of the lungs are filled with blood; also the bronchi; the lining epithelium normal. Spleen, adrenals, kidneys, thyroid, and liver greatly congested; most of the alveoli of the thyroid are empty; in some is a pinkish material (hematoxylin and eosin stain). Sections of the mitral valve show no inflammatory changes.

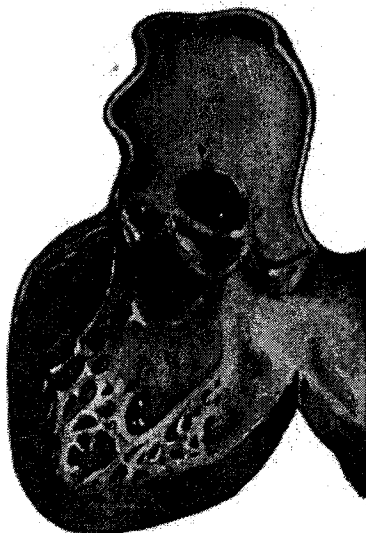

Fig. 3.—Amplified sketch of malformation seen in Fig. 2.

Study of the anomalies of the semilunar valves quickly brings out the unique and peculiar character of the anomaly in this case. Indeed, it is not an anomaly of the aortic valves as much as of the aortic septum. I have found no mention of any similar condition in the literature.²⁷

The most common anomalies of the semilunar valves

are the well-known fenestrations near the free margins, and deviations in number,²⁸ size and form. Other congenital anomalies are very rare, indeed. Dilg²⁹ describes a rare and complicated anomaly: right conus stenosis, two pulmonary semilunars, and stenosis of the conus of the left ventricle produced by a peculiar circular endocardial fold partially subdivided into valves, the shallow, valvular sinuses opening toward the ventricle. Dilg regarded this tendinous ring as an imperfect, second row of valves, the condition resembling somewhat that observed in some of the bony fishes in which the conus arteriosus presents several transverse rows of valves.³⁰

In Banks³¹ case of "perforation of the aortic valves—loud musical murmurs"—the aortic valves were "cribriform," and there were three little rudimentary valves one-quarter of an inch below the aortic orifice. Corrigan,³² in a letter to Banks, attributes the musical murmur to the vibrations of the rudimentary valves.

Röhrle³³ describes a tendinous cord in the aorta of a child. This was the only case of the kind in 25,000 autopsies at the Foundlings' Home in Moscow. The tendinous band originated at the left end of the left semilunar valve, and was stretched quite tightly across part of the lumen of the aorta to the left end of the right semilunar valve. The two ends were thin-like threads; the central part was 0.5 mm. in diameter.

Robert S. Archer³⁴ describes a similar band in a man, aged 39 years. The band was stretched loosely across the lumen of the aorta just above the line of insertion of the aortic valves. It arose by an expansion, one-half inch wide, from the aorta just above the junction of the posterior and left lateral semilunar valves; gradually narrowing, it became inserted at the junction of the posterior and right lateral cusps, thus dividing the area of the vessel into two unequal parts. It seemed to consist of the same kind of tissue as the valves. Otherwise the heart was normal. No clinical observations of the

heart's sounds were made. Archer believes the development of this band in some way was connected with the development of the valves.

Kretz describes an analogous case in which two fibrous bands crossed the aorta from before backward; one, arising from the right aortic valve, was inserted into the concave side of the aortic arch, 3 cm. above the valves; the other crossed the aorta higher up. These bands are regarded as remnants of the partition between the two embryonic aortæ.

Bouillaud³⁵ also describes an aortic band or fold, but I have not been able to secure details. Stintzing³⁶ describes a replacement of one pulmonary segment by two parallel, wholly attached, smooth, narrow bands or ledges extending, one wholly, the other but half way, across the valveless space. Duckworth³⁷ showed a heart with four semilunar valves. "The adventitious valve . . . communicated with one of its fellows at its insertion by an aperture large enough to admit a crow quill."

There is nothing directly comparable with the anomaly in the present case.

The marked leakage under the base of the anterior valve produced hypertrophy of the heart, especially the left side; it also led to marked dilatation of the arterial duct, and, further, to pulmonary and general venous congestion.

The smoothness of the depression at the aortico-septal junction, the normal condition of the coronary artery arising from its bottom, and the well-formed aortic valves tend to the conclusion that the lesion is the result of purely developmental disturbances rather than of intra-uterine aortitis; but the exact genesis of the anomaly is probably not explainable at this late day. One may say, however, that "as with every other anomaly, adequate knowledge will show it to be a natural sequence."

The exact developmental history of the human semi-

lunar valves has not been worked out. According to current teaching,³⁸ four small endothelial cushions appear at the ventricular orifice of the bulbus aortæ before its division into the aorta and pulmonary artery has taken place. Two of these are merely the ends of the ridges by which the aorta is divided (Minot). On completion of the division the two ridges are divided, thus making four protuberances, or in all six—three for each artery. These cushions may be seen in the human embryo of seven weeks (Minot). From them develop, by a process of hollowing out, the semilunar valves.

As already apparent, there is no malformation of the valves proper in this case. The endothelial cushions appear to have developed normally. Possibly the hollowing-out process may have extended to the wall of the aorta, and thus produced the oval depression under the valve, in the same way as Vierordt suggests that communication may be produced between the aorta and the pulmonary artery. It is a little difficult to understand, if this explanation be accepted, how the hollowing-out process could have jumped, as it were, so completely from the valve and out upon the aorta.

We learn further from embryology that the two ridges that divide the primitive aorta extend into the ventricle and help to form the interventricular septum. The aortic septum grows down to the edge of the septum inferius of the ventricle, and thus turns the original interventricular opening into the orifice of the aorta. This is accomplished chiefly by the left or anterior ridge, the right or posterior passing out on the lateral wall of the ventricle, where it is lost. The left ridge, however, runs on to the edge of the septum inferius (Minot). The thinness and the bulging of the aortico-septal junction under the anterior valve may be regarded as indicating a defective development of this part of the aortic septum—the left or anterior ridge. Union with the septum inferius ultimately took place; perhaps the septum

inferius extended further up than usual; but in the meantime the endothelial cushion forming the anterior valve had extended across the defect. The primary endothelial cushions normally grow out until they meet each other. If there were an opening into the right ventricle at the bottom of the present aortico-septal depression no one would hesitate a moment in interpreting the anomaly as the result of a defective aortic septum. No doubt the depression in this case has greatly enlarged, until somewhat resembling an aneurysm, by the pressure of the direct and regurgitating blood streams that passed under the valve. Looking at the case in this way, one may say that defective aortic septum may lead to communication between the aorta and the pulmonary artery, between the aorta and the right ventricle, and between the aorta and the left ventricle under a semilunar valve.

November 12, 1900.

BIBLIOGRAPHY.

1. Arch. of Pediatrics, 1899, xvii, 774-778, and 1900, xviii, 731-736.
2. Lancet, 1830.
3. Transactions London Pathological Society, 1859, vol. II, p. 59.
4. Virch. Arch., 1868, vol. xliii, p. 420.
5. Berl. Klin. Wochenschr., 1879, p. 439.
6. Lancet, 1880, vol. II, p. 768.
7. Ueber einen Fall von congenitaler Communication zwischen Aorta u. arteria pulmonalis. Zurich, Dissertation, 1895.
8. British Medical Journal, 1881, vol. II, p. 71.
9. Gerhardt's Handbuch der Kinderkrankheiten, 1878, iv, Abth. I, p. 61, note.
10. Lehrbuch der Kinderrankheiten, 1874, vol. I, p. 244.
11. See L. Brocq, Etude sur les communications entre l'aorta et l'artère pulmonaire autre que celles qui résultent de la persistance du canal artériel. Revue de Médecine, 1885, vol. v, pp. 1046-1058; 1886, vol. vi, pp. 786-816.
12. Progrès Méd., 1885, 2 ser., vol. II, p. 121.
13. Med. Press and Circular, 1883, vol. xxxv, p. 354.
14. Med. Record, 1883, vol. xxiv, p. 249.
15. Transactions London Pathological Society, 1892, vol. xliii, p. 34.
16. Ibid., p. 36.
17. Bull. de la Soc. Anatomie, 1836, p. 68. Quoted by Taruffi, Sulle malattie congenite e sulle anomalie del cuore. Bologna, 1875, note, p. 102; and by Vierordt, Nothnagel's Specielle Pathologie u. Therapie, 1898, vol. xv, I Theil, II Abth., p. 79.
18. Beiträge zur Entwicklungsgeschichte des Säugethierherzens, Arch. f. Mikr. Anat., 1880, vol. xxxiii, pp. 284-378.
19. Anatomie menschlicher Embryonen, Leipzig, 1880, vol. III, p. 140.
140. Beiträge zur Anatomie des Mensch. Herzens, Leipzig, 1886. See also Minot, Human Embryology, 1897, pp. 521-534.

20. Nothnagel's *Specielle Therapie u. Pathologie*, vol. xv, I Theil, II Abtheil., Die angeborenen Herzkrankheiten, 1898, pp. 138-141.
21. Loc. cit.
22. Loc. cit.
23. Communication cong. entre l'aorta et l'artère pulmonaire sans persistance du canal artériel. Thèse de Paris, 1897.
24. Loc. cit.
25. See Cotton, loc. cit.
26. At the autopsy the irregularities were thought to be due to endocarditis, and it was so stated in the anatomical diagnosis.
27. Potain and Rendu (anomalies de l'orifice aortique, article cœur, Dictionnaire encyclopedique des sciences médicales, 1878, vol. xviii, p. 571); Marchand (Eulenberg's Realencyclopædie, 1897); Peacock (Malformations of Human Heart, 1866); Taruffi (Sulle malattie congenite e sulle anomalie del cuore, 1875), and H. Vierordt (Nothnagel's Path. u. Ther., 1898, vol. xv) do not mention any anomaly resembling this.
28. Peacock, loc. cit. Osler, Bicuspid condition of aortic valves. Transactions Association of American Physicians, 1886, vol. 1, p. 185.
29. Virch. Arch., 1883, vol. xci, p. 193.
30. Gegenbauer: Lehrb. der Anat. des Menschen, Leipzig, 1883, p. 625.
31. Dublin Hospital Gazette, 1857, vol. iv.
32. Ibid., p. 49.
33. Chorda tendinæ in aorta, Deut. Med. Wochenschr., 1896, p. 270.
34. Notes on a congenital band stretching across origin of aorta. Dublin Journ. of Med. Sci., 1878, vol. lxxv, p. 405.
35. Bull. de l'Acad. de Méd., 1862-63, vol. xxviii, p. 777.
36. Ueber eine seltene Anomalie der Pulmonalklappen. Deut. Arch. f. Klin. Med., 1889, vol. xlii, p. 149.
37. Trans. London Path. Soc., 1886, vol. xvii, p. 113.
38. Born, Arch. f. Mikr. Anat., 1889, vol. xxxiii, p. 284-287. His Beiträge zur Entwicklungsgeschichte des Säugethierherzens. Tonge, Observations on the development of the semi-lunar valves of the aorta and pulmonary artery of the heart of the chick. Proc. of Royal Soc. of London, 1868, vol. xvi, p. 335. Minot, Human Embryology, 1892, p. 534.