

ON A CASE OF MULTIPLE FOCI OF INTERSTITIAL MYOCARDITIS IN HEREDITARY SYPHILIS.

By LUDWIG HEKTOEN, M.D., Chicago.

From Prof. Chiari's Pathological Institute, Prague.

ACQUIRED syphilis not unfrequently produces changes in the heart; in hereditary syphilis, on the other hand, the heart very rarely seems to be involved, and the number of cases of hereditary syphilitic heart lesions described in the literature is exceedingly small.

No statistics bearing upon this point seem to exist. Petersen¹ found syphilitic heart changes ten times in a statistical material of 88 cases of mostly acquired syphilis, but he makes no attempt to consider separately hereditary heart syphilis.

Mueller² examined the bodies of 18 syphilitic infants, but he makes no mention of having observed any changes in the heart.

In the recent study of heart syphilis by Mraček³ are collected, from the literature of the subject, 112 cases of this lesion, but of this number only 9 (von Rosen, Williams, Wagner, Morgan, Kantzow Virchow, Money, Shattock, Coupland, Orth) are described in connection with hereditary syphilis, and the luetic nature of some of these is certainly very doubtful, to say the least. Mraček, furthermore, studied the material furnished by 150 post-mortem examinations of congenitally syphilitic infants, and the outcome, so far as the heart is concerned, consists of four examples of congenital syphilitic myocarditis, two being mentioned as representing a nodular or more gummatous form, the other two illustrating a more diffuse, acute, interstitial variety.

Since the publication of Mraček's work, it has not been possible to find any further cases in the accessible literature of the last year or two.

Partly in order to add a new case to the meagre literature of hereditary syphilitic heart lesions, partly in order to show in a strik-

¹ "Versuch einer path.-anat. Statistik der visceralen syphilis," *Monatsh. f. prakt. Dermat.*, Hamburg, 1888, s. 109.

² "Beiträge zur pathol. anatomie der syphilis hereditaria bei Nengeborenen," *Virchow's Archiv*, bd. xcii. s. 532.

³ "Die Syphilis der Herzene bei erworbener und ererbter Lues," *Arch. f. Dermat. u. Syph.*, Wien, Ergänzungsheft ii. 1893.

ing manner the remarkable extent that such processes may reach, it has been thought advisable to publish the following instance of interstitial myocarditis in a luetic infant, the organs of which were kindly placed at my disposal for microscopic examination by Professor Chiari, whom I hereby thank for his advice during the preparation of this report.

The case was that of a female child 6 weeks old, from the clinic of Professor Ganghofner, which showed, when 4 weeks old, a macular exanthema that soon developed into pemphigus; at the same time diarrhoea and exhaustion set in, and rapidly caused death. It was the first child, and there was no history of previous abortions. The clinical diagnosis was hereditary syphilis.

POST-MORTEM EXAMINATION.—The body is 45 cm. long, of feeble build, and quite emaciated. The skin is everywhere covered with small, dried vesicles or brownish crusts. On the back there are a few pale livid patches. The rigor mortis is well marked. The hair is brownish, thick; the pupils equal and slightly dilated. The neck is short and thin; the thorax long and broad. The abdomen is of normal dimensions. The scalp is anæmic; the skull, 35 cm. in horizontal circumference, is normally ossified; the dura is everywhere adherent to the calvaria; in the dural sinuses there is dark red, fluid blood. The pia and the brain are without any changes. The diaphragm reaches, on the right side to the upper, on the left side to the lower, border of the fifth rib.

The mucous membrane of the mouth, pharynx, and larynx is normal. The thymus and thyroid glands are of proportionally normal size. The lungs are partly distended, partly collapsed, dark red in colour, firm in consistence; a small amount of yellow muco-pus can be squeezed out of the bronchi.

In the pericardium there are no abnormal contents, and the layers are smooth and shining.

The heart corresponds fairly in size relatively to that of the body; the myocardium is pale, and the walls of the ventricles are somewhat thickened, the right measuring 6 mm., the left 11 mm., and the ventricular septum 7 mm., in thickness. The left ventricle is 3.5 cm., the right 3 cm., in depth. In the walls of the ventricles are numerous whitish, round areas, which are quite sharply circumscribed, and cause slight bulgings of the surface here and there; the cut surface of these areas is of a homogeneous appearance; there are no signs of any disintegration, they are not calcified, and there is no encapsulation; they cut with perhaps a little more resistance than the normal-looking heart muscle. These areas vary very much in size, the largest measuring 1 cm. They occupy in about the same number the anterior and posterior walls of both the ventricles, and are distributed thickly throughout the interventricular septum; they bear no constant relation to the vessels. The auricles do not show any changes.

The macroscopic coronary arteries appear healthy.

The heart valves are thin and smooth, and there are no developmental defects or anomalies in the heart or the larger vessels.

The liver is quite large, yellowish-brown, of homogeneous appearance on the cut surface.

The spleen is also somewhat enlarged, quite firm, partly deep red, partly brown in colour.

The kidneys are normal in size, light grey in colour, of usual consistence, and without any naked-eye changes.

The ureters, bladder, and genital organs are normal.

In the stomach there is a small amount of brownish fluid, the mucous membrane is pale. The mucous lining of the ileum is a little reddened and swollen.

The pancreas and the adrenals show no changes.

The line of ossification in the lower line of the femur is not quite sharp and straight, but rather broad and yellowish.

Anatomical diagnosis.—Congenital syphilis.

(Exanthema, enlargement of liver and spleen, gumata of the heart, osteo-chondritis.)

Catarrhal bronchitis.

Partial pulmonary atelectasia.

Acute catarrhal enteritis.

MICROSCOPIC EXAMINATION.—*The heart.*—Vertical segments, running from base to apex, were cut out of the right and the left halves of the

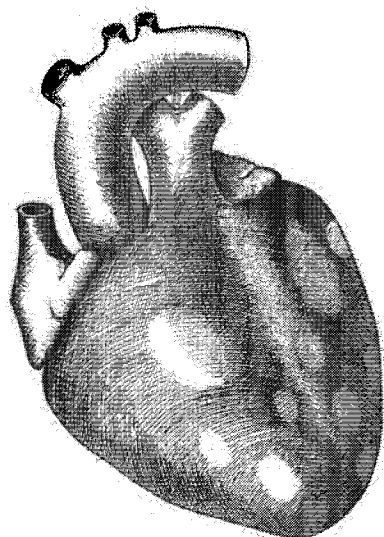


FIG. 1.—The anterior surface of the heart. The lighter areas show the foci of interstitial myocarditis.




FIG. 2.—The posterior surface of the heart. The lighter areas show the foci of interstitial myocarditis.

anterior wall of the right ventricle, of the anterior and the posterior halves of the left margin of the left ventricle, and of its posterior wall, and of the anterior and posterior halves of the interventricular septum.

The whitish foci seen upon these sections from the heart walls were indicated upon diagrammatic outlines, in order to control the topographic relations of the possible microscopic changes. It was found that without any exception the microscopic changes, about to be detailed, corresponded exactly to the whitish, more or less circumscribed areas, noted in the naked-eye description.

The changes consist in an extensive infiltration into and between the muscular bundles, with rounded and oval nucleated cells, usually embedded in a fibrillated stroma. This infiltration occurs, as indicated, in quite large, fairly-circumscribed districts, and seems to proceed in the main from the adventitia of the smaller vessels, immediately around which the proliferation is usually most marked, and from which more or less distinct strands of young connective tissue pass into the adjacent tissue. The larger sub-

epicardial vessels are not involved; it is only the finer branches in the heart muscle that are concerned in these changes; the vessels are nearly always empty and contracted; there is no proliferation of endothelial lining, and the vessel walls are rarely infiltrated, but the adventitia contains more and denser fibrous tissue than is found in normal hearts from young infants examined for the purposes of control. The media of the smaller arteries is also considerably thickened.

The muscular fibres in the area of proliferation show an indistinct striation, the nuclei are usually distinct, but in many places the infiltration separates individual fibres, and in such it is usually difficult to recognise the typical structure. Only in one or two places,—and these were in the interventricular septum,—did the proliferation appear in the form of a distinctly nodular accumulation of cells; in one of these the centre showed an ill-defined degeneration, with appearances that reminded one of a necrotic giant cell, otherwise the proliferation is diffuse, but confined to the districts indicated in the drawings. There is no distinct fibrinous exudate in the changed areas, as no fibrin can be found in sections stained according to Weigert's fibrin method; neither are there any leucocytes with polymorphous nuclei.

The epicardium is not changed. The endocardium shows, very distinctly, accumulations of endothelial cells, in the recesses between the papillary muscles.

In the *lungs* the bronchi contain exudate with leucocytes and desquamated epithelial cells. In places there is collapse of the parenchyma with hyperæmia.

The *liver* has much increase of connective tissue in Glisson's capsule, and also a marked intralobular interstitial proliferation.

In the *spleen* there is dilatation of the venous sinuses, and some increase in the lymphoid elements.

The *kidneys* show no changes.

In the *lower* end of the *femur* there is a minimum degree of irregularity in the line of ossification.

REMARKS.—In the foregoing case we have an instance of multiple areas of interstitial myocarditis in a syphilitic child. The diagnosis of syphilis is based, not only upon the clinical manifestations, but also upon the firmest anatomical basis, to wit, the cutaneous eruption, the connective tissue proliferation in the liver, the splenic tumour, and the osteo-chondritis.

In the *heart* the interstitial changes were so marked, and so sharply defined, that it led to the anatomical diagnosis of gummata of the heart; in fact, the microscopic examination shows that the centres of some of the areas present the changes characteristic of gumma. This case is consequently one of nodular, or gummatous myocarditis in hereditary lues; as additional instances of this form of congenital syphilitic heart lesion, reference may be made to two cases described by Mraček.¹

While the clinical history of this case points to the cachexia, and the intestinal derangement as the causes of death, it cannot be denied that such an extensive focal myocarditis as has been described must in itself be a most dangerous lesion, in consequence of which death might ensue at any moment, no matter what the general condition of nourishment might happen to be.

¹ *Loc. cit.*

In fact, the case of congenital syphilitic myocarditis described by Coupland,¹ and one of the cases of acute exudative myocarditis in congenital syphilis described by Mraček,² both show sudden death in two children, that had previously been regarded as in good general health. In both these cases the changes in the myocardium were more acute and more diffuse than in the case here described; they were also accompanied by exudation of serum and fibrin.

It is evident that the dangerous nature of congenital syphilitic myocarditis, including, as shown, the liability to sudden death in apparently healthy children, adds an element of practical and clinical interest to such lesions, which is of much greater weight than that which they have previously possessed as mere curiosities in pathological anatomy.

¹ "Specimens from a Case of Infantile Syphilis, Interstitial Myocarditis, and Nephritis, Gummata in the Liver and the Lung," *Trans. Path. Soc. London*, vol. xxvii. p. 303.

² *Loc. cit.*

Note.—There is no ground for the assumption ventured by Mraček that Coupland's case is one of congenital malformation with consecutive hypertrophy of the heart. There is nothing in Coupland's description to indicate any defect in the ventricular septum, as Mraček suspects. In another place, Mraček speaks of Coupland's case as a possible gumma of the heart, whereas it is as pure and evident an instance of congenital syphilitic myocarditis as any on record.